PROCEDURE 40

Arthroscopic Treatment of Osteochondritis Dissecans of the Knee

Scott D. Gillogly and Phillip R. Langer

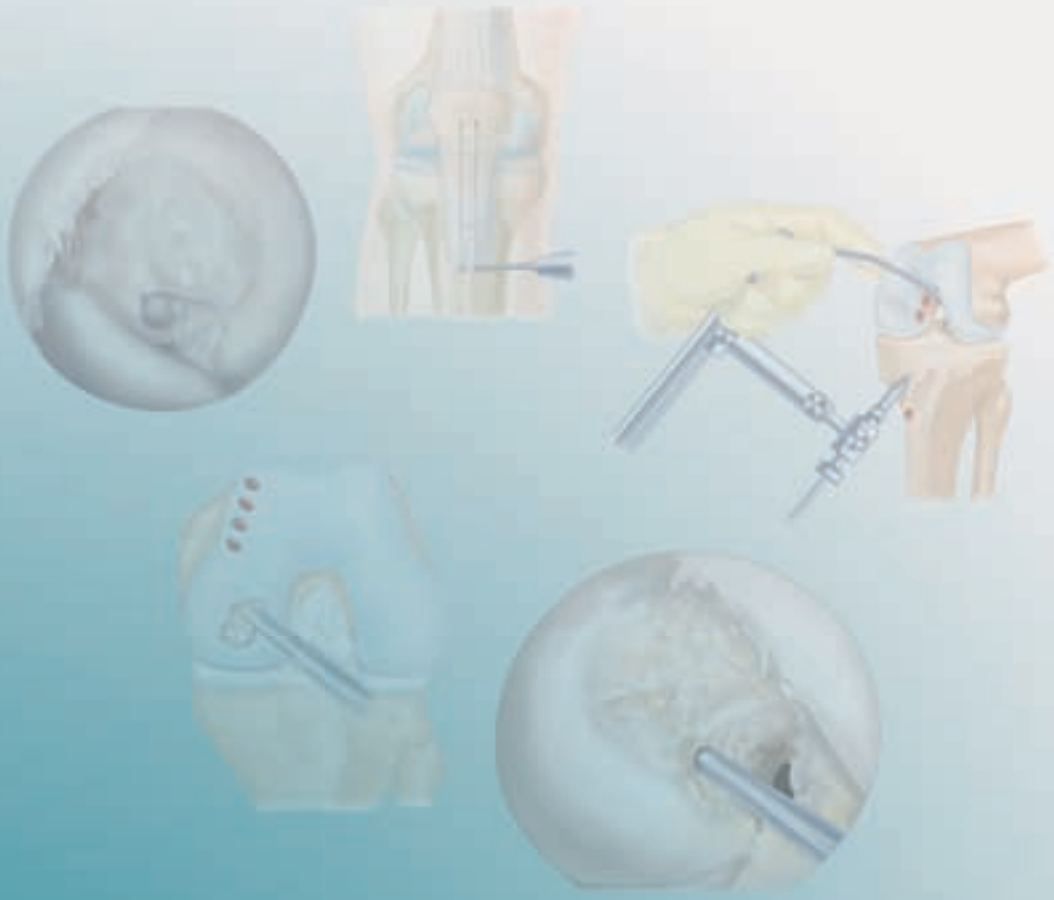

PITFALLS

- *Contraindications to arthroscopy (i.e., indications for open arthrotomy, though examination still starts with arthroscopy)*
  - *Massive lesions (>3 cm^2)*
  - *Large ± multiple loose bodies*
  - *Anatomic inaccessibility to arthroscopy*

Indications

- Decisions regarding treatment of osteochondritis dissecans (OCD) of the knee follow an outcome-based classification system that accounts for the patient's age and the stability, location, and size of the lesion.
- Category 1: Preadolescent children (open physes): girls ≤11 years; boys ≤13 years
  - Nonoperative treatment
  - Excellent prognosis
- Category 2: Near skeletal maturity: girls 12–20 years; boys 14–20 years
  - Lesion stability dictates treatment
  - Intermediate prognosis
- Category 3: Skeletally mature (closed physes): girls/boys greater than 20 years
  - Grade of the lesion determines treatment (Clanton and DeLee, 1982):
    - Grade 1: Depressed osteochondral fracture
    - Grade 2: Osteochondral fragment attached by an osseous bridge
    - Grade 3: Detached nondisplaced fragment
    - Grade 4: Displaced fragment (loose body)
  - Poorest prognosis
  - Possible sequelae:
    - Lesion instability leading to loose bodies
    - Bone loss
    - Secondary bony deformity
- This chapter only addresses arthroscopic interventions for OCD. Consequently, allograft transfers and autologous chondrocyte implantation (ACI), which require an arthrotomy, are not covered.

Examination/Imaging

- Pertinent physical examination findings and symptoms
  - ± Effusion
  - ± Quadriceps atrophy/weakness
  - ± Palpable loose body causing mechanical locking/catching/"giving way"
  - Affected region: diffuse tenderness to palpation
  - Forcible compression of affected side causing crepitus
  - Lateral femoral condyle lesions causing painful "clunk" during range of motion
  - Patella lesions: retropatellar pain/crepitus

Treatment Options

- Universal Principle (1-4): preserve articular cartilage
  - Stable lesion in a skeletally immature patient: nonoperative treatment
  - Intact lesion: drilling (antegrade, retrograde)
  - Partially detached/salvageable lesion: fixation ± bone graft (bone defect)
  - Loose, in situ lesion: fixation ± bone graft (bone defect)
  - Small unsalvageable lesion: loose body removal, debridement + marrow stimulation/drilling
  - Large unsalvageable lesion: excision + osteochondral autograft transfer versus chondral biopsy for staged ACI
  - Lesion with absent articular cartilage + bone deficiency: bone graft, fibrin glue

- Wilson's test: internal rotation of the tibia at 30° of knee flexion produces pain; external rotation relieves pain
  - Gait: tibia held in external rotation to unload affected area

■ Plain radiographs
- Multiple diagnostic views should be obtained: anteroposterior, lateral, tunnel, and axial.
- Skeletally immature patients require contralateral comparison views.
  - Bilateral incidence is 20–25% (Schenck and Goodnight, 1996).
  - Note: multiple lesions require further evaluation to rule out endocrine abnormalities and multiple epiphyseal dysplasia.
- The pathognomonic presentation is a well-circumscribed area of sclerotic subchondral bone with a radiolucent line between the defect and the epiphysis.
- A sclerotic base indicates fragment instability (poor prognosis).
  - Figure 1 shows a persistent OCD defect of the lateral femoral condyle in a 17-year-old male after arthroscopic pinning with absorbable pins (Fig. 1A). Note the lucency between the OCD bone fragment and the remainder of the condyle (Fig. 1B). On magnetic resonance imaging (MRI) (Fig. 1C), the pin tracks are still visualized traversing the center of the bone fragment and fliud is evident (*arrows*) between the fragment and condyle.
  - Figure 2 shows a 22-year-old male with a persistent lateral femoral condyle OCD lesion (*arrow*) on an anteroposterior radiograph (Fig. 2A); bony changes such as these usually correspond to full thickness cartilage loss, as seen in Figure 2B.
- Anteroposterior view
  - Medial femoral condyle lesions are typically posterolateral, intersecting the intercondylar notch.
  - Lateral femoral condyle lesions are larger and more posterior, and involve the weight-bearing surface.
- Tunnel view: the best image to visualize medial femoral condyle lesions

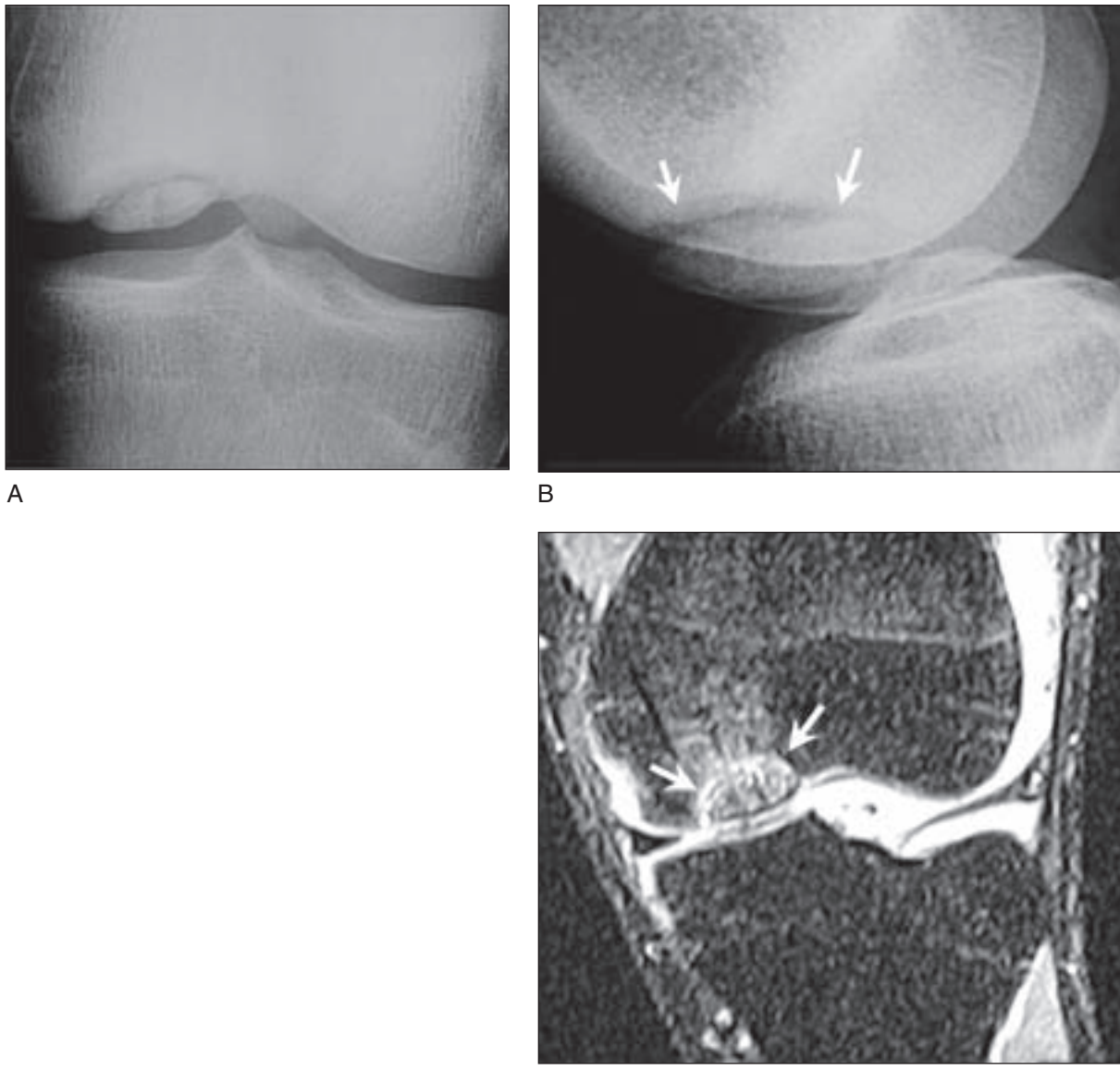

A B C

FIGURE 1

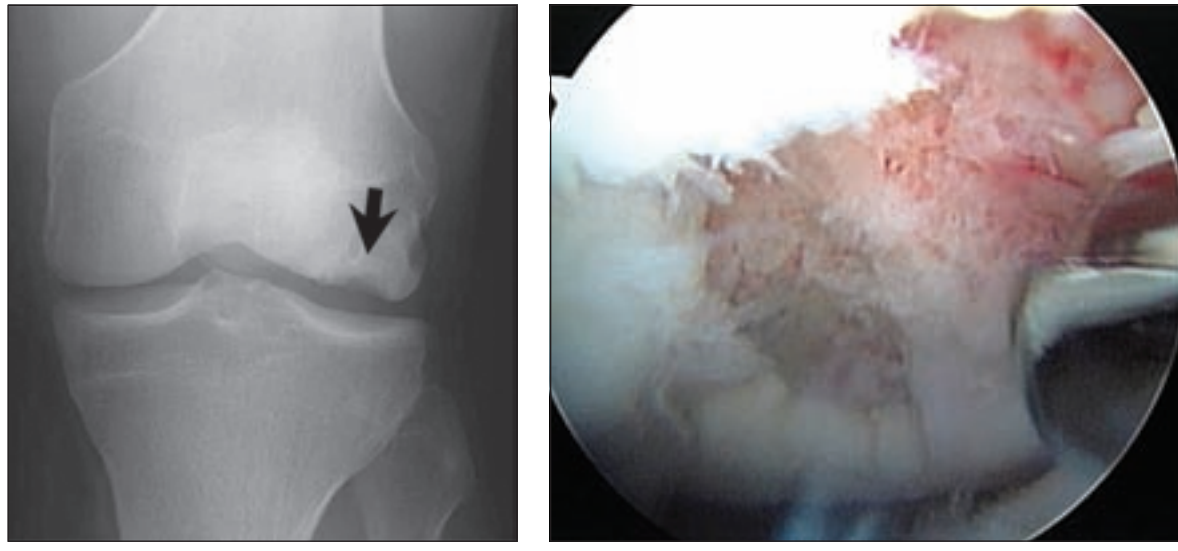

FIGURE 2 A B

- Lateral view
  - Medial femoral condyle lesions lie within an arc outlined by the posterior femoral condyle and Blumensaat's line.
  - Patella lesions are typically inferior.
- Axial view: patella lesion

- Arthrography is not routinely used.
- Bone scans
  - Highly sensitive
  - Prognostic indicator: close correlation between radionucleotide uptake and healing potential
    - Good prognosis: increased uptake (increased vascularity)
    - Poor prognosis: normal scan in the presence of abnormal radiographs
- MRI
  - Provides excellent detail of the articular integrity.
  - Useful for staging OCD lesions and identifying loose bodies.
  - Correlates well with arthroscopic findings.
  - Determines size, viability, and stability of the subchondral bone fragment.
    - On a T_2-weighted image, a bright signal between the fragment and subchondral bone reveals the presence of synovial fluid, indicating an unstable lesion (see Fig. 1C).
  - Gadolinium enhancement is used to evaluate healing and revascularization.
- Computed tomography scans
  - Use when MRI is unavailable or contraindicated
  - Provide excellent bony detail, but cannot assess fragment separation
- Knee arthroscopy
  - Has both diagnostic and therapeutic uses.
  - Allows direct visual inspection of the size and stability of the lesion (see Fig. 2B).
    - Apparent stable lesions on radiographs may be loosely adherent with arthroscopic probing.
    - Allows assessment of micro-motion: intact cartilage, but unstable bony base, allowing indentation with compression by arthroscopic probe.
  - Sequential arthroscopic examinations allow tracking to follow healing.

Surgical Anatomy

- Anatomic locations of OCD in the knee (Fig. 3)
  - Medial femoral condyle
    - 80–85% of cases
    - Lateral, non–weight-bearing (NWB) surface (i.e., posterolateral aspect)
  - Lateral femoral condyle
    - 10–15% of cases
    - Posterior aspect, weight-bearing (WB) surface
  - Patella
    - 5% of cases
    - Inferior aspect
  - Trochlea (quite rare)
- Obtain preoperative images to locate the lesion.
  - Contralateral views can be helpful, especially in juvenile patients, to better visualize the relationship of the physis to the lesion.

Positioning

- Place the patient in the supine position.
  - Pad the contralateral limb to prevent potential pressure necrosis.
  - Place the operative thigh against an arthroscopy post or in a circular thigh immobilizer.
  - If a circular immobilizer is used, drop the end of the table so that both limbs dangle at 90°.
- Place a tourniquet high on the operative extremity.
  - Pay attention to the perineal region during application to avoid genital impingement.

Pearls

- *Apply a firm elastic wrap around the operative leg and calf to resist extravasation of fluid in the event there is a concomitant capsular tear (possibly problematic with excessive pressure if a pump inflow vs. gravity system is used).*

Pitfalls

- *Make sure to position the patient so that a valgus force may be applied to the knee while it remains in full extension (i.e., does not buckle into flexion).*

Equipment

- Any arthroscopy post or circular thigh immobilizer can be used. Devices such as the Arthrex or Smith and Nephew position devices/posts are most commonly used.

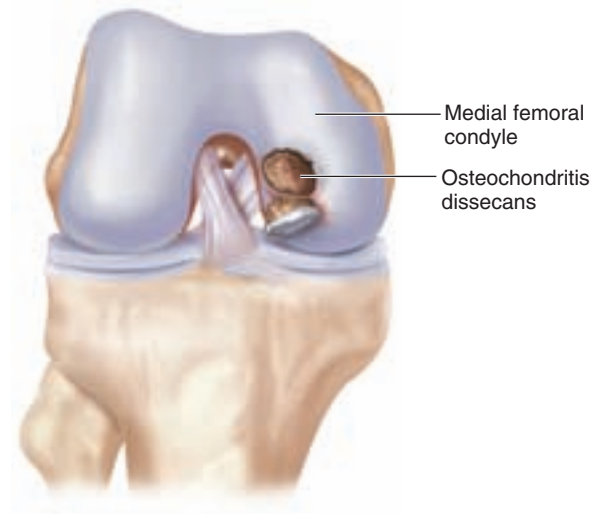

FIGURE 3

Pearls

- *Anterolateral/anteromedial portal: incision*
  - *When using a knife, horizontally direct the blade away from the patellar tendon.*
  - *Once the blade is buried beneath the skin, rotate it 90° to gently vertically incise the capsule.*
- *Anterolateral/anteromedial portal: fat pad*
  - *If the fat pad is prominent and obstructing visualization, resist the urge to shave it away.*
  - *Instead, attempt to "push and pull" the scope into either the notch or the supracondylar pouch to pull the fat pad anteriorly out of the field of vision.*

Portals/Exposures

- Anterolateral portal (Fig. 4)
  - Most important portal
  - Initial site for scope insertion
- Anteromedial portal
  - Visualization of the lateral compartment
  - Instrumentation of the medial compartment
- Superomedial portal
  - Inflow cannula if gravity system used
    - Note that, with modern pump equipment, the inflow cannula is generally not necessary.
- Superolateral portal
  - Use to view the patellofemoral articulation dynamics
- Posteromedial portal
  - Located in the small, triangular soft spot formed by the posteromedial edge of the tibia and posteromedial margin of the femoral condyle, 1 cm above the posteromedial joint line

Pitfalls

- *Too large a portal incision size allows loss of excessive fluids and consequent poor capsular distention.*

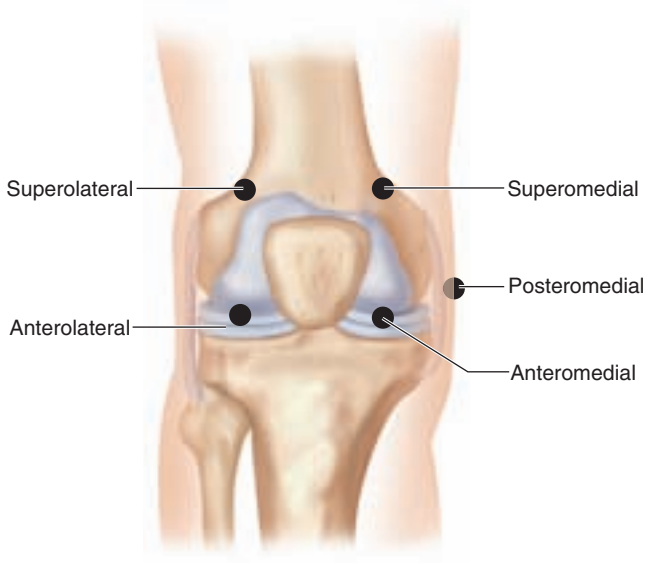

FIGURE 4

Management Decisions

- To simplify management decisions, divide patients into two groups based on the classification system described in the Indications section.
  - "Juvenile/young adult" = categories 1 and 2 (patients ≤20 years old)
  - "Adult" = category 3 (patients >20 years old)

Treatment

- Basic tenets
  - Decrease pain.
  - Increase subchondral bone healing potential.
  - Maintain intact articular cartilage.
  - Fix unstable fragments, restore articular congruity (decreases degenerative joint disease risk).
  - Replace damaged bone/cartilage with implant tissues/cells.
- Improved prognosis with younger age and NWB location
  - Exception: patellar OCD, in which prognosis is not directly related to age but rather dependent on lesion size
- Juvenile/young adult group
  - Stable intact lesion: surgery with arthroscopic drilling if (1) nonoperative treatment fails or (2) there is no radiographic sign of healing after 12 weeks
  - Unstable lesion: surgery regardless of age
- Adult group
  - Surgery regardless of lesion stability
- Treatment options for unstable juvenile/young adult group lesions or adult group lesions:
  - Small lesion in NWB area: excise; débridement + marrow stimulation vs. fixation
  - Early separated lesion: fixation ± graft (bone defect)
    - Bioabsorbable pins
    - Cannulated screws
    - Autogenous bone pegs (e.g., Osteochondral Autograft Transfer System [OATS])
  - Partially detached lesion: hinge open; débridement + marrow stimulation ± bone graft + fixation
  - Crater with loose bodies and salvagable lesion: débridement + marrow stimulation ± bone graft + fixation
  - Crater with loose bodies and unsalvagable lesion: excision ± OATS/débridement + marrow stimulation/drilling versus ACI/allograft (2,3)

- Lesion ≤2–2.5 cm^2: OATS versus débridement + marrow stimulation/drilling
- Lesion >2.5–10 cm^2: ACI versus OATS versus allograft plugs
- Lesion >10 cm^2: fresh allograft versus total knee replacement versus high tibial osteotomy

- Patella OCD: excision + curettage/drilling versus fixation

Pearls

- *If the patient is not fully skeletally mature, take every precaution to avoid the open physis.*
- *Utilize fluoroscopy to locate a lesion that is intact with little or no articular change.*

Procedure: Arthroscopic Drilling of an Intact Condylar Lesion

Step 1: Diagnostic Arthroscopy

- Begin with a thorough systematic diagnostic arthroscopy using a 30° arthroscope via the anterolateral portal.
- Carefully inspect the integrity of the femoral condyle articular surface.
  - Increase the degree of flexion (typically from 20° to 90°) to visualize the posterior extent of the lesion. The articular surface will appear smooth if the lesion is intact except for a slightly raised irregularity at the borders of the defect.
  - Confirm your suspicion to be sure there is no break in the continuity of the articular surface overlying the subchondral bone lesion with tactile investigation via a probe placed through the anteromedial portal.
- If the lesion is intact, use a smooth 0.062-inch Kirschner wire (K-wire) to perforate the defect with multiple holes (thereby increasing the vascularity).
  - Drilling options: anterograde, retrograde, computer-assisted navigation

Step 2A: Anterograde Approach (via the Articular Cartilage)

- Place the K-wire perpendicular to the articular surface to avoid undermining the remainder of the lesion. Protect the surrounding soft tissues by a sleeve or cannula over the wire.
- The location of the lesion and which condyle(s) are affected will determine through which portal (anteromedial vs. anterolateral) to insert the K-wire.
- Large lesions may require some drilling through both anteromedial and anterolateral portals—possibly even an additional accessory portal.

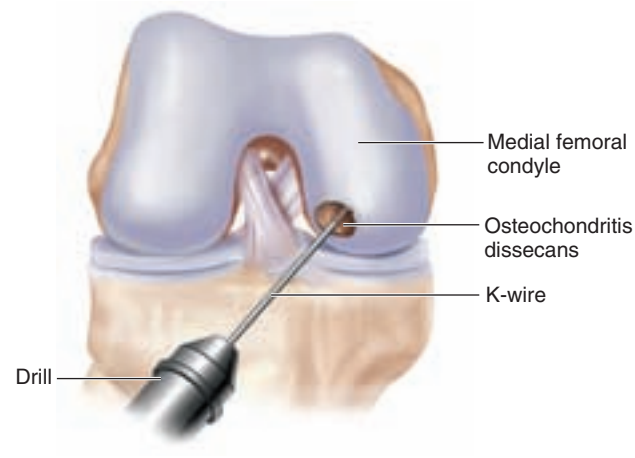

FIGURE 5

- Penetrate the articular surface, the subchondral lesion, and the underlying bone 1–1.5 cm to ensure vascular access to the defect by passing the calcified tidemark (Fig. 5).
- Place the drill holes several millimeters apart.

Step 2B: Retrograde Approach

- This approach is advocated to avoid penetration of the articular cartilage.
- Principles are similar to the anterograde approach.
- Use fluoroscopy to identify the location of the lesion and for placement of the smooth 0.062-inch K-wire.
- An ACL Tibial Guide may provide assistance in proper placement of the K-wire.

Step 2C: Computer-Assisted Navigation for Retrograde Drilling

- In this relatively experimental minimally invasive approach, computed tomography images are obtained with a three-dimensional navigation system to determine the target point of the OCD.
- The real markers are indicated with the pointer and related to the virtual markers on the image data set.
- The targeting device is adjusted as the pointer is introduced into the aiming device.
- The movements of the pointer are detected by a camera and depicted on a monitor
- Finally, using the targeting device guidance, a smooth 0.062-inch K-wire is drilled into the lesion.

Controversies

- Retrograde drilling theoretically avoids the articular cartilage. It is technically more challenging to avoid the distal femoral physis and avoid penetrating the articular cartilage while reaching the calcified tidemark using this technique.
- Antegrade drilling is technically easier, permitting a perpendicular approach to the lesions and direct visualization of the drilling site. Drilling through the articular cartilage with a smooth 0.062-inch K-wire produces minor damage to the overlying articular cartilage.

Procedure: Arthroscopic Loose Body Removal, Débridement + Marrow Stimulation/Drilling vs. Chondral Biopsy for a Staged ACI

Step 1: Diagnostic Arthroscopy

- Perform a diagnostic arthroscopy and inspect the defect.
- If an OCD loose body or bodies are identified, carefully inspect the detached lesion and its crater base to determine the viability of the cartilage and bone.
- If the lesion is unsalvageable (e.g., rounded off, unable to fit congruously within the crater, completely detached and nonviable, ±comminuted), extract the fragment(s).

Step 2: Arthroscopic Loose Body Removal

- Slowly flex and extend the knee to flush out hidden loose bodies.
  - The posteromedial portal is helpful to check for loose bodies.
- It may be necessary to enlarge the anteromedial/anterolateral portal to remove the fragment(s) depending on their size.
- If the loose body has been detached for some time, the base of the crater already may be covered by a white fibrocartilaginous tissue.
  - Do not remove this tissue
  - Use a smooth 0.062-inch K-wire to drill and perforate the underlying cortical bone.
- If the loose body recently became detached from the osteochondritic bed, an essentially bare sclerotic cortical bone surface will be present.
- Carefully smooth and contour the edges and walls of the crater with an arthroscopic shaver ± ring curette without removing additional healthy articular cartilage.

Step 3A: Débridement + Marrow Stimulation/Drilling

- This technique is used if the defect size is ≤2–2.5 cm^2.
- Clear any fibrous debris from the base of the crater with an arthroscopic shaver ± curette.

- Use one of the following techniques to stimulate the release of growth factors/stem cells from the bone marrow:
  - Perforate with multiple drill holes using a 0.062-inch K-wire placed at a 90° angle. Figure 6 shows a medial femoral condyle OCD defect in a 20-year-old male (Fig. 6A) that was treated with marrow stimulation (Fig. 6B).
  - Perform a microfracture to break the subchondral bone using an awl with different curves to come in with a 90° angle.
  - Abrade the surface to bleeding cancellous bone using an arthroscopic shaver ± burr.

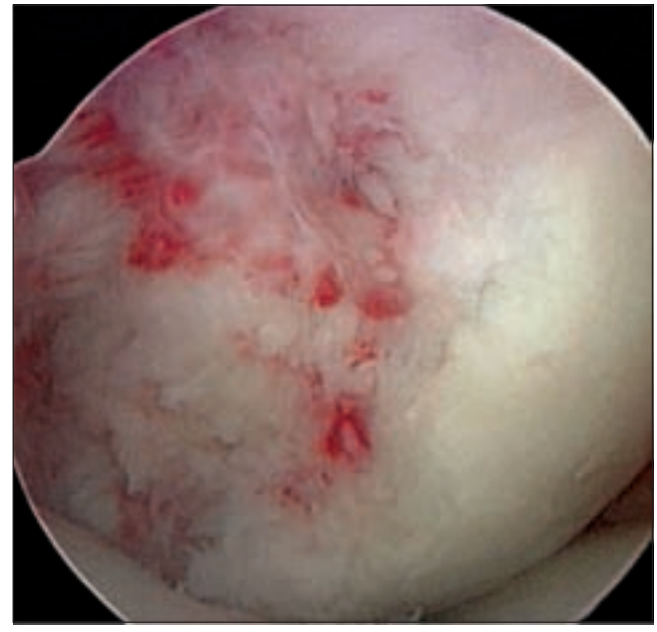

A

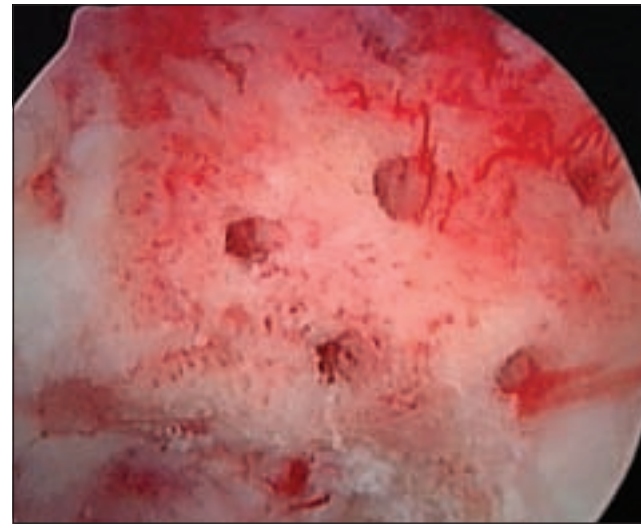

B

FIGURE 6

Pearls

- *ACI indications*
  - *Contained lesion less than 10 cm²*
  - *Patient age 15–50 years*
  - *No inflammatory arthritis*
  - *Patient willingness and ability to comply with the postoperative rehabilitation program*
  - *Stable or correctable knee*
  - *Normal or correctable tibiofemoral and patellofemoral alignment*

Step 3B: Chondral Biopsy for a Staged ACI

- This technique is used if the size of the lesion is >2.5–10 cm^2.
- Biopsy healthy articular cartilage from a NWB area of the medial or lateral femoral condylar ridge for laboratory culture of additional chondrocytes.
- Approximately 11–21 days later, once the cultured chondrocytes have grown to 2.6–5 million cells, they are ready for implantation.
- ACI is used in cases such as the trochlea OCD lesion in a 16-year-old female that has displaced with multiple loose bodies shown in Figure 7A. The lesion was débrided (Fig. 7B) and a chondral biopsy obtained for staged ACI.
  - This second surgical procedure requires an arthrotomy of the knee and, therefore, is not covered because it is beyond the desired arthroscopic focus of this chapter.

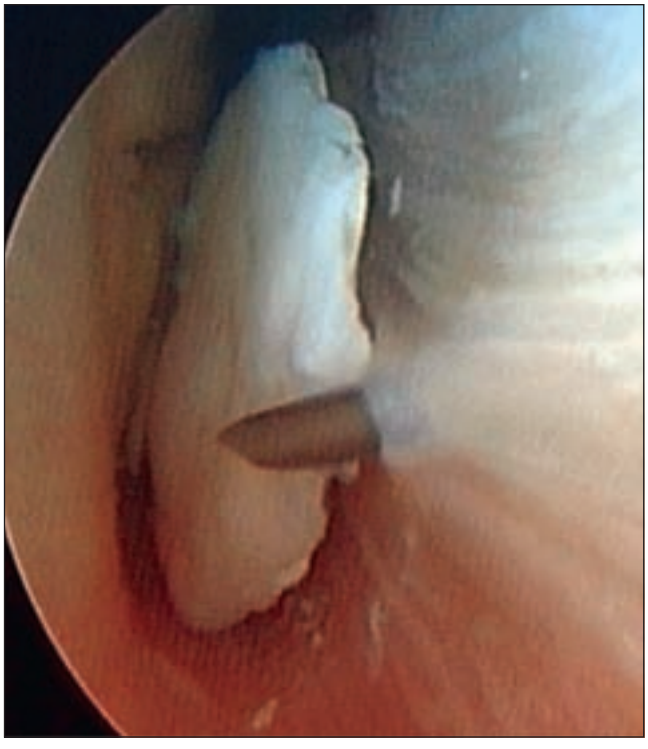

A

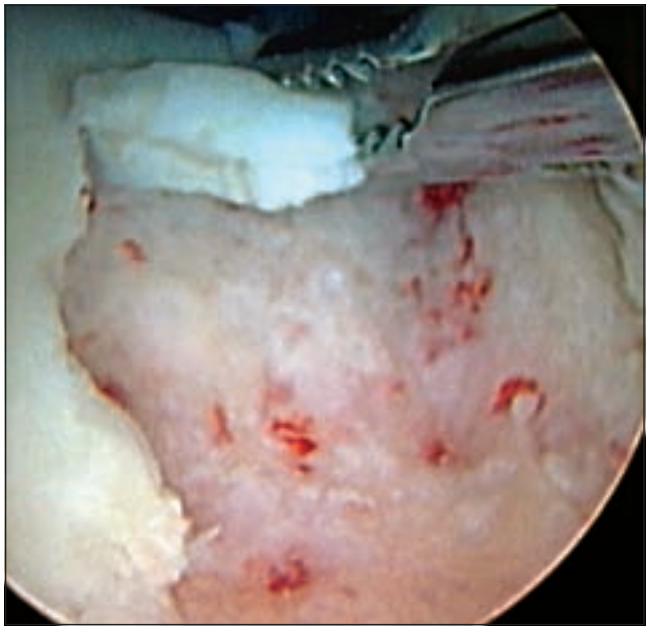

B

FIGURE 7

Procedure: Arthroscopic Fixation ± Bone Graft

Step 1: Diagnostic Arthroscopy

- Perform a systematic arthroscopy of the knee and probe the lesion.
- If it is a loose, in-situ lesion, fix it.
- If it is a partially detached or salvageable completely detached lesion, curette the base of the crater to fresh cancellous bone, and carefully fit the fragment back into its bed.
- Fixation options vary depending on the size and stability of the lesion.

Step 2A: Small, Relatively Stable Lesion

- A small, relatively stable lesion is secured with smooth 0.062-inch K-wires or an absorbable fixation device.
- K-wire technique (Lipscomb method):
  - Insert two or three smooth 0.062-inch K-wires through the lesion in different directions, emerging on the outer surface of the affected femoral condyle.
  - In skeletally immature patients, take care to avoid the physes.
  - Withdraw the wires until the ends of the pins disappear just below the surface of the articular cartilage.
  - Cut the proximal ends of the pins long and bury them beneath the skin.
  - Remove the pins once the lesion has healed on radiographs.
- Bioabsorbable fixation:
  - Provisionally align the lesion with smooth 0.062-inch K-wires.
  - Bioresorbable fixation options include:
    - Bioresorbable bone fixation nail (e.g., SmartNail)
    - OATS plugs
    - Bionx nail
    - Autogenous matchstick-sized strips of corticocancellous bone graft
- Figure 8 shows an OCD “trap door” flap in a 14-year-old male (Fig. 8A) with about half of the perimeter cartilage still intact that was treated with marrow stimulation of the accessible bone and absorbable 1.6-mm darts providing firm fixation (Fig. 8B).

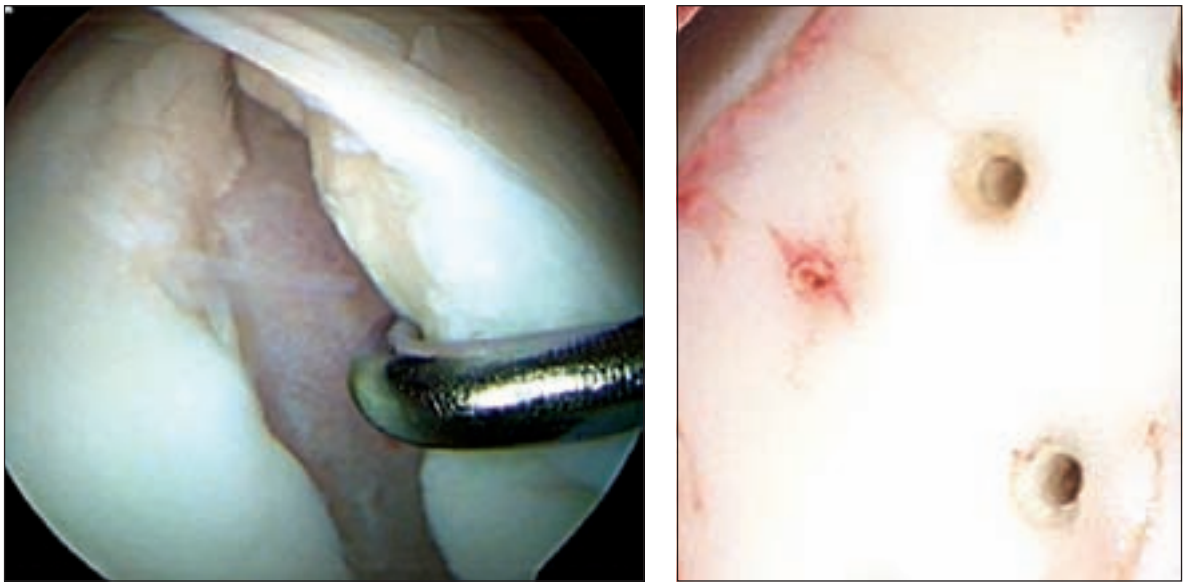

A B

FIGURE 8

Step 2B: Large Lesion with Firm Crater

- A large lesion with a firm crater is stabilized with a compression screw, either an Accutrac, Herbert, or Synthes 4-mm cannulated screw. Use one or more screws as needed depending on the size and fragmentation of the lesion.
- If the crater is covered with a thin layer of fibrous tissue, clean it and abrade the crater to reposition the fragment.
- If the lesion has loose fragments, use an arthroscopic burr to freshen the basal side of the fragment and crater. Be careful to avoid abrading too much because the fragment can sink and cause articular incongruency.
- Use image intensification to confirm the correct location of the screw(s).
- Insert the appropriate screw guide and make a perforation through it.
- Measure the length of the screw and insert it.
- If only one screw is required, back it up with an absorbable pin to increase rotational stability.
- Make multiple perforations with a 2-mm bit after placing the screw(s).

Pearls

- *The external reaming bone grafting technique may be useful in large, deep, radiolucent lesions in adults. Do not use this technique in skeletally immature patients if the physis is open.*

Instrumentation/ Implantation

- Use smooth 0.062-inch K-wires because they are less likely to break and are easier to remove; however, unlike threaded pins, there is a migration risk.

Step 2C: Lesion with Significant Bone Loss

- If bone loss is significant, cancellous bone graft is required prior to fragment fixation to obliterate stepoff.
- Direct arthroscopic placement
  - Use a trephine coring needle or similar device to harvest cancellous graft from the proximal tibia.
  - Pack the graft into the base of the crater to a smooth surface before reduction and fixation of the lesion.
- External reaming
  - Use one of the fixation pins as a guide pin for a cannulated reamer.
  - Pass the selected 0.062-inch K-wire from the articular surface through the avascular fragment, through the femoral condyle, and out through the epicondylar area.
  - Make a small skin incision over the tip of the wire and insert a small cannulated coring reamer over the wire.
  - Carefully ream a channel toward the articular surface.
  - Use an image intensifier to determine the proper depth to penetrate, by means of the channel, the sclerotic bone opposite the subchondral avascular fragment.
  - Do not penetrate to the surface.
  - Remove the graft from the coring reamer.
  - Pack cancellous bone graft down the reamed channel so that fresh cancellous bone chips are immediately behind the avascular osteochondritic lesion.
  - Secure the fragment.
- In a symptomatic medial femoral condyle OCD in a 14-year-old male, radiographs (Fig. 9A and 9B) and MRI (Fig. 9C) demonstrated a large OCD lesion with bony fragmentation.
  - At arthroscopy (Fig. 10A and 10B), the articular cartilage showed early breakdown at the periphery of the lesion, especially posterior and medial. There was gross motion of the defect but no loss of articular cartilage.

A

B

C

FIGURE 9

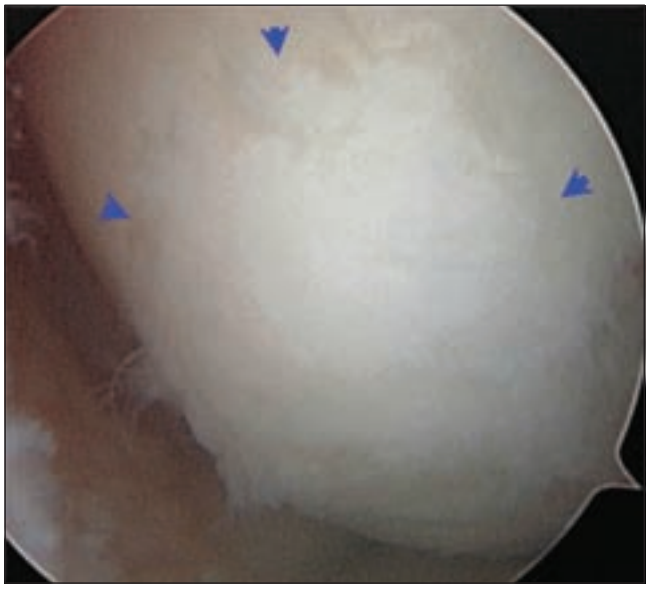

A

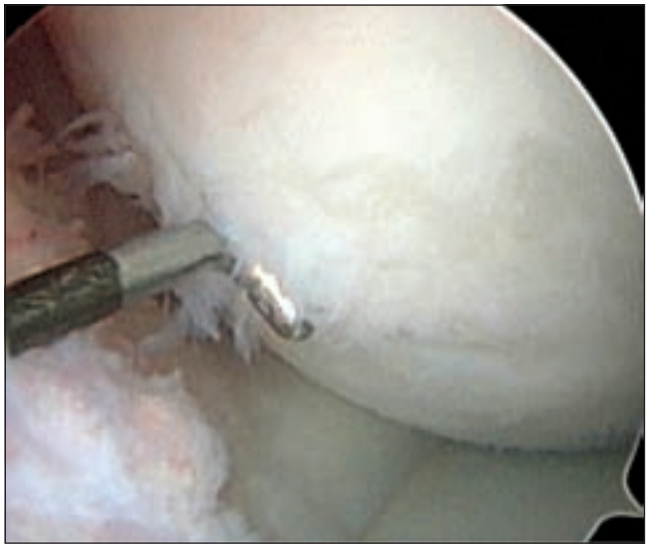

B

FIGURE 10

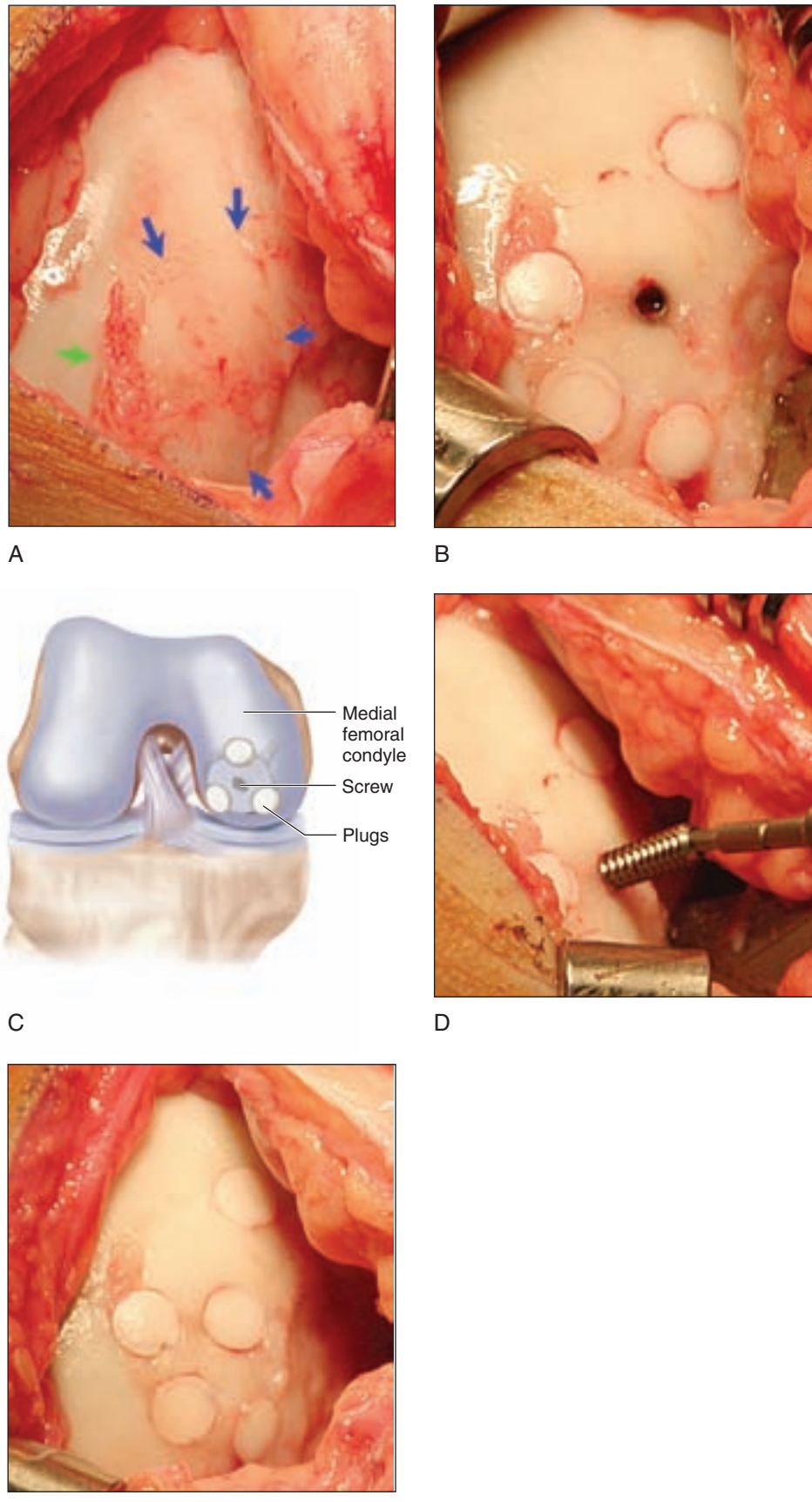

FIGURE 11

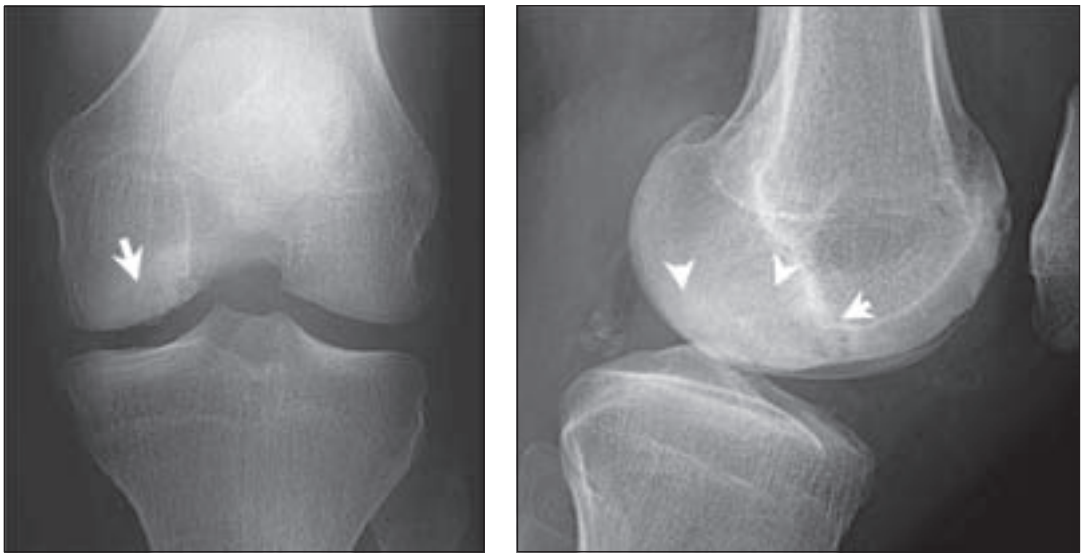

A B

FIGURE 12

- A mini-arthrotomy (Fig. 11A) allowed access to the lesion, where a temporary screw was placed. Osteochondral plugs of healthy bone and cartilage were used to "stabilize" and bone graft the lesion (Fig. 11B and 11C). The temporary screw was removed (Fig. 11D) and replaced with a final osteochondral plug (Fig. 11E).
- Radiographs at 30 months postoperative (Fig. 12A and 12B) show healing and incorporation of the OCD lesion to the medial femoral condyle, with the patient returned to full activity.

Procedure: Autologous Osteochondral Transfers

Step 1

- Two similar systems are available; the difference is core size.
  - Arthrex: individual donor cores 5–10 mm in size
  - Smith and Nephew: smaller plugs 2.7–8.5 mm in size
- Use a set of OATS sizer/tamps with 5- to 10-mm heads to precisely measure the diameter of the defect.
- The color-coded tamps correspond in size with the diameter of the tube harvesters.
- Assemble the tube harvester driver/extractor.
- Load the donor tube harvester with the collared pin into the base of the driver and tighten the chuck.
- Screw a cartilage protector cap onto the back of the driver.

Pearls

- *OATS indications*
  - *Age less than 45 years*
  - *Sharply defined, contained lesion*
  - *Unipolar lesion*
  - *Defect size less than 2–2.5 cm²*
  - *Crater depth less than 1 cm*
  - *No inflammatory arthritis*
  - *Patient willingness and ability to comply with the postoperative rehabilitation program*
  - *Stable knee*
  - *Normal tibiofemoral and patellofemoral alignment*

- When seated, the collared pin will protrude a few millimeters past the sharp cutting tip of the harvester to protect the articular surface.

Controversies

- Indications for arthrotomy vs. arthroscopic approach (debated)
  - Defect size greater than 1.5 cm in diameter
  - Lesions in which more than half is posterior to the center of the WB surface: the required flexion angle makes visualization difficult; the patella may become an obstacle
- Some advocates believe that smaller plugs cause less trauma to the donor site and can be plugged into the recipient site to restore an area about 2 cm in diameter.
- Some proponents believe the larger grafts fill the recipient site with more cartilage and can be used in defects ranging from 1 cm to 2.5 cm.
- Many researchers think that the most advantageous size graft is between 4.5 and 6.5 mm.

Step 2

- Obtain the donor graft from either the supracondylar ridge or intercondylar notch.
- Drive the donor harvester with a mallet into subchondral bone or to an approximate depth of 15 mm. Take care to avoid rotating the harvester during impaction.
- Axially load the harvester, rotating the driver 90° clockwise, then 90° counterclockwise, to remove the harvester and bone core.

Step 3

- Fully insert the recipient harvester into the driver and insert the protector caps in a similar fashion.
- During socket creation, maintain a 90° angle to the articular surface to end up with a flush transfer.
- Rotate the harvester so the depth markings are seen.
- Take care to maintain a constant knee flexion angle during harvesting.
- After using a mallet to drive the tube harvester into subchondral bone to a depth of approximately 13 mm (2 mm less than the length of the donor core), extract the recipient bone core in the same manner as the donor bone core and measure and record the depth of the core
- Use the calibrated OATS alignment stick of the appropriate diameter to measure the recipient socket depth and correctly align the angle of the recipient socket in relation to the position of the insertion portal when using an arthroscopic approach

Pearls

- *Each core transfer should be completed before creating additional recipient sockets. This will prevent potential recipient tunnel wall fracture and allow subsequent cores to be directly placed in close proximity to previously inserted bone cores.*

PITFALLS

- *Eccentric plug placement*
- *Protruding or recessed osteochondral plugs*

STEP 4

- Reinsert the donor harvester, collared pin, and autograft core into the driver.
- Unscrew the cap and remove the T-handled midsection to expose the end of the collared pin that is used to advance the bone into the recipient socket.
- Insert the pin calibrator over the guide pin and press into the open back of the driver.
- Insert the donor tube harvester's bevelled edge fully into the recipient socket.
- Stabilize the harvester during autograft impaction.
- Use a mallet to lightly tap the end of the collared pin and drive the bone core into the recipient socket. Make sure to maintain a stable knee flexion angle and position of the harvester.
- Carefully advance the collared pin until the end of the pin is flush with the pin calibrator on the back of the driver/extractor.
  - This provides exact mechanical control to ensure proper bone core insertion depth.
  - The predetermined length of the collared pin is designed to advance the bone core so that 1 mm of graft will be exposed from the recipient socket when the pin is driven flush with the end of the pin calibrator.

STEP 5

- Remove the donor tube harvester and position a sizer tamp, measuring at least 1 mm in diameter larger than the diameter of the bone core, over the bone core.
- Lightly tap the tamp with a mallet to seat the bone core flush with surrounding cartilage.

Postoperative Care and Expected Outcomes

- Postoperative care is dependent on technique.
  - Universal (regardless of type of treatment): immediate straight leg raises and isometric exercises
    - Initial straight leg raises are resistance free; add 2–3 lbs per week until 10% of body weight is reached.
    - Institute a 6- to 8-week program: range of motion (ROM), stretching, progressive strengthening, functional or sport training.

- No running/jumping sports are allowed until there is radiographic evidence of healing.
- Low-impact activities are allowed (walking, submaximal biking, swimming).
- Initiate closed kinetic chain exercises at week 6.

- Arthroscopic drilling of intact lesion
  - Immobilize the patient in a restricted-motion brace. Adjust the arc of motion to prevent contact of the tibial articular surface with the lesion.
  - Crutches and toe-touch WB are maintained until radiographic healing is seen.
  - With radiographic evidence of healing, initiate ROM exercises 20 minutes, three times per day.
- Arthroscopic fixation
  - Do not immobilize the patient.
  - Start isometric exercises the same day.
  - Keep the affected limb NWB for 10 weeks.
- Arthroscopic removal of loose bodies from a NWB area
  - Do not immobilize the patient.
  - Allow WB as tolerated. Exception: with débridement + microfracture/drilling, keep NWB for 3 weeks.
  - Use continuous passive motion (CPM) for 6 weeks.
- Arthroscopic removal of loose bodies in a WB area
  - Do not immobilize the patient.
  - Keep the patient NWB for 6 weeks; progress to full WB by 12 weeks.
  - Initiate ROM exercises.
  - Use CPM for 6 weeks.
- Autologous osteochondral transfers
  - Use an unloading knee brace (controversial: some advocate no immobilization).
  - Keep the patient NWB for 6 weeks.
  - Initiate ROM exercises.
  - Use CPM for 6 weeks.

■ Complications
- OCD nonunion
- Loose bodies
- Degenerative joint disease
- Patella arthrofibrosis
- Hemarthrosis
- Effusion
- Pain
- Condylar fracture
- Osteonecrosis

- Return to play
  - Radiographic evidence that OCD lesion has healed
  - Normal physical examination (ROM, quadriceps strength, no effusion/thrombotic thrombocytopenic purpura)
  - Asymptomatic

Evidence

Clanton TO, DeLee JC. Osteochondritis dissecans: history, pathophysiology and current treatment concepts. Clin Orthop Relat Res. 1982;(167):50-64.

This classic paper, which classifies OCD into grades 1-4, suggests that the grade of the lesion determines treatment.

Detterline AJ, Goldstein JL, Rue JP, Bach BR Jr. Evaluation and treatment of osteochondritis dissecans lesions of the knee. J Knee Surg. 2008:21:106-15.

This paper discussed the etiology of knee OCD lesions, clinical presentation, proper evaluation, and current treatment options. Physicians must consider many factors, including the patient's age and skeletal maturity, as well as size, location, and stability of OCD lesions, to determine the proper course of treatment.

Emmerson BC, Görtz S, Jamali AA, Chung C, Amiel D, Bugbee WD. Fresh osteochondral allografting in the treatment of osteochondritis dissecans of the femoral condyle. Am J Sports Med. 2007;35:907-14.

This study reviewed a case series of 66 knees in 64 patients with OCD of the femoral condyle treated with fresh osteochondral grafting. Each patient was evaluated both preoperatively and postoperatively using an 18-point modified D'Aubigné and Postel scale. Subjective assessment was performed using a patient questionnaire. Radiographs were evaluated preoperatively and postoperatively. Mean follow-up was 7.7 years (range, 2-22 years). (Level IV evidence [case series])

Gudas R, Kalesinskas RJ, Kimtys V, Stankevicius E, Toliusis V, Bernotavicius G, Smailys A. A prospective randomized clinical study of mosaic osteochondral autologous transplantation versus microfracture for the treatment of osteochondral defects in the knee joint in young athletes. Arthroscopy. 2005;21:1066-75.

This study compared the outcomes of mosaic-type osteochondral autologous transplantation (OAT) and microfracture (MF) procedures for the treatment of articular cartilage defects of the knee joint in a total of 60 athletes with a mean age of 24.3 years. There were 28 athletes in the OAT group and 29 athletes in the MF group. The mean duration of symptoms was 21.32 ± 5.57 months, and the mean follow-up was 37.1 months (range, 36-38 months). Patients were evaluated using modified Hospital for Special Surgery (HSS) and International Cartilage Repair Society (ICRS) scores, radiographs, MRI, and clinical assessment. An independent observer performed a follow-up examination after 6, 12, 24, and 36 months. At 12.4 months postoperative, arthroscopy with biopsy for histologic evaluation was carried out. A radiologist and a pathologist, both of whom were blinded to each patient's treatment, did the radiologic and histologic evaluations. (Level I evidence [prospective randomized clinical study])

Kocher MS, Czarnecki JJ, Andersen JS, Micheli LJ. Internal fixation of juvenile osteochondritis dissecans lesions of the knee. Am J Sports Med. 2007;35:712-8.

This study reviewed a case series of 26 knees in 24 skeletally immature patients who underwent internal fixation of OCD lesions. Functional and radiographic outcomes were followed up at an average of 4.25 years. (Level IV evidence [case series])

Lebolt JR, Wall EJ. Retroarticular drilling and bone grafting of juvenile osteochondritis dissecans of the knee. Arthroscopy. 2007;23:794.

This study presented an effective technique for retroarticular drilling and bone grafting of juvenile OCD. Major advantages of this technique include the ease of harvest/transfer of autograft, readily available instrumentation to perform the procedure, and the ability to avoid violation of stable articular cartilage.

Miniaci A, Tytherleigh-Strong G. Fixation of unstable osteochondritis dissecans lesions of the knee using arthroscopic autogenous osteochondral grafting (mosaicplasty). Arthroscopy. 2007;23:845-51

This study reviewed 20 patients with OCD lesions fixed in situ by using multiple 4.5-mm osteochondral dowel grafts harvested from the edges of the femoral trochlea. The follow-up averaged 18 months. (Level IV evidence [case series])

Miura K, Ishibashi Y, Tsuda E, Sato H, Toh S. Results of arthroscopic fixation of osteochondritis dissecans lesion of the knee with cylindrical autogenous osteochondral plugs. Am J Sports Med. 2007;35:216-22.

This study reviewed the clinical results and MRI findings of 12 knees with OCD lesions treated with in situ fixation with autogenous osteochondral plugs. The follow-up averaged 4.5 years. (Level IV evidence [case series])

Murray JR, Chitnavis J, Dixon P, Hogan NA, Parker G, Parish EN, Cross MJ. Osteochondritis dissecans of the knee: long-term clinical outcome following arthroscopic debridement. Knee. 2007;14:94-8.

This study reviewed 32 knees in 26 patients who had previously undergone arthroscopic débridement for symptomatic OCD of the knee. The patients were followed up at a minimum of 11 years after surgery and were evaluated clinically using the American Knee Society Clinical Rating Score, Hughston Scale, and radiographic assessment.

Schenck RC Jr, Goodnight JM. Osteochondritis dissecans. J Bone Joint Surg [Am]. 1996;78:439-56.

This study reviewed OCD of knee, detailing its etiology, incidence, and natural course of history.

Weckström M, Parviainen M, Kiuru MJ, Mattila VM, Pihlajamäki HK. Comparison of bioabsorbable pins and nails in the fixation of adult osteochondritis dissecans fragments of the knee: an outcome of 30 knees. Am J Sports Med. 2007;35:1467-76.

MRI and clinical evaluation were used to review the medium-term outcome of 28 patients (30 knees) with OCD of the knee treated with arthroscopic fixation of the fragment using bioabsorbable, self-reinforced poly-L-lactide pins and nails. The average follow-up time was 5.4 years. (Level III evidence [cohort study])